



# A Unique Case with Tracheal Atresia Among Published Literature on TACRD and VACTERL Associations

## TACRD ve VACTERL Birliktelikleri Hakkında Yayınlanmış Literatürler Arasında Trakeal Atrezili Özgün Bir Olgu

✉ Sabri Cansaran, ✉ Cengiz Gül, ✉ Shukri Said Mohamed, ✉ Ayşenur Celayir

University of Health Sciences Turkey, Zeynep Kamil Maternity and Children's Diseases Health Training and Research Center, Department of Pediatric Surgery, İstanbul, Turkey

### ABSTRACT

Tracheal atresia/agenesis (TA) is associated with other congenital anomalies (TACRD and/or VACTERL). In this study, a female newborn with TA who had all the elements associated with TACRD and VACTERL was reported. The patient with TA, tracheo-esophageal fistula (TEF) connecting to the esophagus at the level of the carina, persistent left superior vena cava, duodenal atresia, vertebral and limb defects, bilateral hydronephrosis, and persistent cloaca was operated on postnatal 5<sup>th</sup> day. Band ligation to the abdominal esophagus, gastrostomy, duodenal atresia repair and diverting colostomy due to persistent cloaca were performed. The lungs were bilaterally expanded in the first postnatal, preoperative and postoperative chest radiographs. Oxygen saturation remained above 90% until the patient died suddenly on the postnatal 8<sup>th</sup> day. TA is a very rare congenital anomaly that causes postnatal respiratory distress. This case is unique among the literature on TACRD and VACTERL associations for many reasons. Esophageal band ligation in TA cases with TEF is a method that keeps the pressure in the esophagus at an appropriate level and provides air passage to the trachea via fistula.

**Keywords:** Duodenal atresia, newborn, TACRD, tracheal atresia/agenesis, VACTERL

### ÖZ

Trakeal atrezi/agenezi (TA) diğer konjenital anomalilerle (TACRD ve/veya VACTERL) ilişkilidir. Bu çalışmada, TACRD ve VACTERL ile ilişkili tüm özelliklere sahip TA'lı bir kız yenidoğan raporlandı. TA, özofagus karina seviyesinde bağlanan trakeo-özofageal fistül (TEF), persistan sol superior vena kava, duodenal atrezi, vertebra ve ekstremitte defektleri, bilateral hidronefroz ve persistan kloaka tanılı hasta postnatal 5. günde opere edildi. Abdominal özofagus bant ligasyonu, gastrostomi, duodenal atrezi onarımı ve persistan kloaka nedeniyle diverjan kolostomi uygulandı. Postnatal ilk, preoperatif ve postoperatif çekilen grafilerde akciğerler bilateral ekspanseydi. Hastanın oksijen saturasyonu, postnatal 8. gündeki ani ölümüne kadar, %90'ın üzerinde kaldı. TA, postnatal solunum sıkıntısına neden olan, çok nadir görülen bir konjenital anomalidir. Bu olgu, birçok nedenden dolayı, TACRD ve VACTERL birliktelikleri ile ilgili literatür arasında benzersizdir. TEF'li TA olgularında özofagus bant ligasyonu özofagus bant basıncı uygun seviyede tutan ve fistül yoluyla trakeaya hava geçişini sağlayan bir yöntemdir.

**Anahtar kelimeler:** Duodenal atrezi, yenidoğan, TACRD, trakeal atrezi/agenezi, VACTERL

Received: 03.03.2023

Accepted: 30.03.2023

### Corresponding Author

Sabri Cansaran,  
University of Health Sciences  
Turkey, Zeynep Kamil Maternity and  
Children's Diseases Health Training  
and Research Center, Department of  
Pediatric Surgery, İstanbul, Turkey  
✉ sabrican@hotmail.com

ORCID: 0000-0001-8466-6595

**Cite as:** Cansaran S, Gül C, Mohamed SS, Celayir A. A Unique Case with Tracheal Atresia Among Published Literature on TACRD and VACTERL Associations. J Dr Behcet Uz Child Hosp. 2023;13(2):142-145

## INTRODUCTION

Tracheal atresia/agenesis (TA) is a very rare congenital anomaly that causes postpartum respiratory distress and subsequent difficulties with endotracheal intubation<sup>(1)</sup>. The trachea below the larynx is completely or partially absent, and tracheo-esophageal or broncho-esophageal fistulas of varying shapes are usually seen.

Despite advances in surgical treatment methods, the mortality rate in TA is high, and about 85% of children with TA die within two days after birth<sup>(2)</sup>. The diagnosis is often made at post-mortem examination.

Concomitant tracheo-esophageal or broncho-esophageal fistulas allow ventilation and resuscitation after esophageal intubation. After birth, a timely diagnosis and effective airway treatment are essential for patients' survival<sup>(3)</sup>.

Although the cause of TA is still unknown, it is often associated with the components of TACRD (tracheal agenesis, cardiac, renal and duodenal malformations) and VACTERL (vertebral anomalies, anal atresia, cardiovascular anomalies, trachea-esophageal fistula (TEF), esophageal atresia, renal/radial anomalies, limb defects) associations<sup>(4)</sup>. In this study, a female newborn



with TA who had all the elements associated with TACRD and VACTERL was reported.

## CASE REPORT

A female baby weighing 1,800 grams, born from a 27-year-old mother at the 34<sup>th</sup> gestational week, who was followed up with the diagnoses of Down syndrome, duodenal atresia and anomaly of great vessels in the antenatal period, was emergently consulted to the Department of Pediatric Surgery due to respiratory and endotracheal intubation difficulties. Abdominal “double bubble” appearance and left persistent superior vena cava were reported in the prenatal ultrasound. In the laryngoscopy performed during the initial evaluation, it was observed that the tracheal lumen was closed just distal to the vocal cords. Good ventilated lungs after esophageal intubation suggested the diagnosis of TA with TEF. Extremity anomalies and persistent cloaca were also detected in the patient. After the patient was stabilized, the lungs were bilaterally expanded in the X-ray, and also the diagnosis of duodenal atresia was confirmed with the abdominal “double bubble” appearance (Figure 1).

During the follow-up period in the neonatal intensive care unit, the patient underwent thoracic computed tomography on the postnatal 3<sup>rd</sup> day. The diagnosis of Floyd type II TA was confirmed by computed tomography. It was observed that the tracheal segment distal to the

vocal cords was agenetic, and the main bronchi were connected to the esophagus with a fistula at the level of the carina (Figure 2). Thus, the patient had all the components of TACRD and VACTERL associations due to the diagnosis of other diseases such as persistent left superior vena cava, duodenal atresia, vertebral and limb defects, bilateral hydronephrosis, and persistent cloaca accompanying TA with TEF.

The patient, whose oxygen saturation was above 90% and who was clinically stable during the follow-up, was operated on the postnatal 5<sup>th</sup> day when the deteriorated coagulation parameters returned to the normal range. The lungs were bilaterally expanded in the preoperative chest X-ray (Figure 3). The patient underwent esophageal band ligation, which was expected to create intraluminal ventilation pressure provided by duodenal atresia in the preoperative period, gastrostomy, duodenal atresia repair, and colostomy due to persistent cloaca. The lungs were also bilaterally expanded in the postoperative chest X-ray (Figure 3), and no early complications were observed. The patient died on the postnatal 8<sup>th</sup> day due to sudden worsening of clinical condition and cardiac arrest.

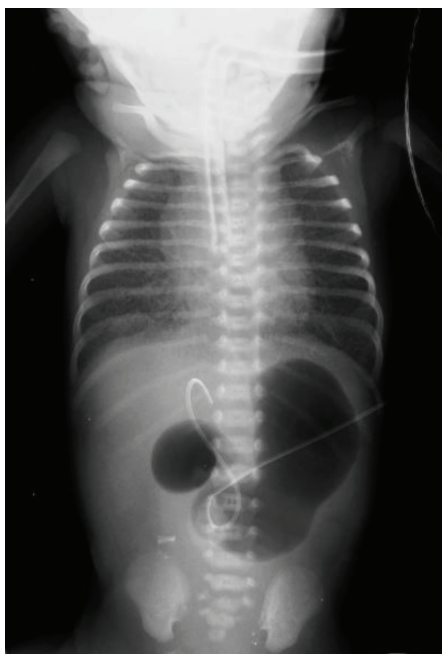
During the hospital stay, informed consent was obtained from the patient’s family that scientific studies could be conducted in the future.

## DISCUSSION

The estimated incidence of tracheal abnormalities is two per 100,000 live births including severe congenital stenosis and atresia. Fewer than 100 cases have been recorded in the medical literature to date, and Payne reported the first case identified in 1900<sup>(5)</sup>. Floyd et al.<sup>(6)</sup> divided TA into three groups according to its severity. In type 1 TA (13%), the distal trachea is connected to the esophagus with a fistula. The carina opens directly into the esophagus in type 2 TA (65%). In type 3 TA (22%), both main bronchi open into the esophagus separately (Figure 2)<sup>(1,6)</sup>.

The endoderm of the proximal foregut produces the trachea as a ventral protrusion. The original ventral respiratory diverticulum descends to create the trachea, links with the sixth aortic arch, and splits distally. It is encircled by angiogenic mesenchyme. Total to partial foregut cleavage failure is thought to cause TA<sup>(7)</sup>.

Although most researchers claim the presence of at least three components for diagnosis, there is still no consensus on definitive diagnostic criteria for the VACTERL association. The exact etiology of the



**Figure 1.** Postnatal first chest and abdominal X-ray

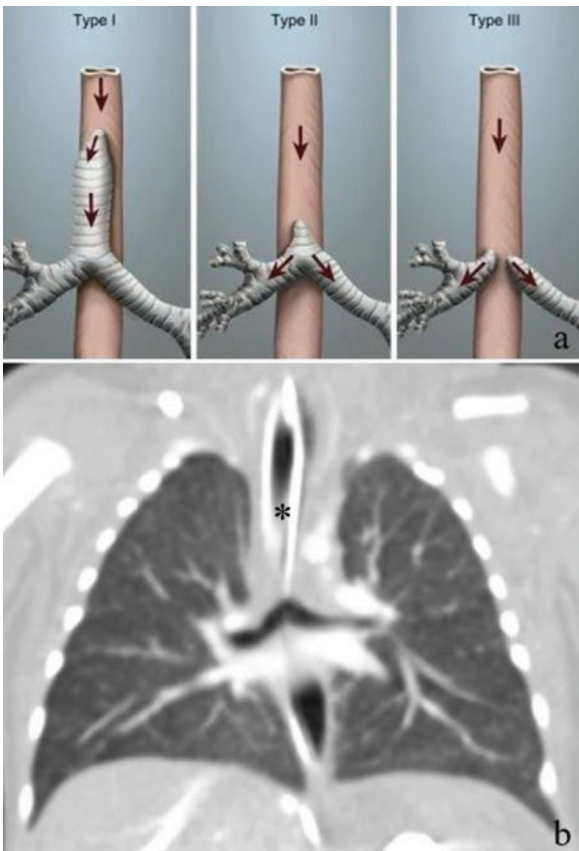
VACTERL association is unknown. Its pathophysiology may include faulty mesodermal development during embryogenesis leading to overlapping symptoms. Possible causes include maternal diabetes, teratogenic medications, physical stress, uterine vascular disease, infertility treatment, and the use of oral contraceptives in the first trimester<sup>(8)</sup>. Furthermore, some authors believe that TA is not part of the VACTERL association, but that TA is one of the malformations in a different association pattern known as TACRD, which includes complex congenital heart anomalies, renal anomalies, and duodenal atresia<sup>(9)</sup>.

In the delivery room, during the first postnatal examination, TA should be included in the differential diagnosis in newborns who do not cry and have findings such as apnea and difficulty in intubation<sup>(10)</sup>. Respiratory decompensation due to gastric decompression should primarily suggest an unusual airway anatomy. Gastric decompression can reduce esophageal pressure and airflow to the lungs due to high resistance TEF in

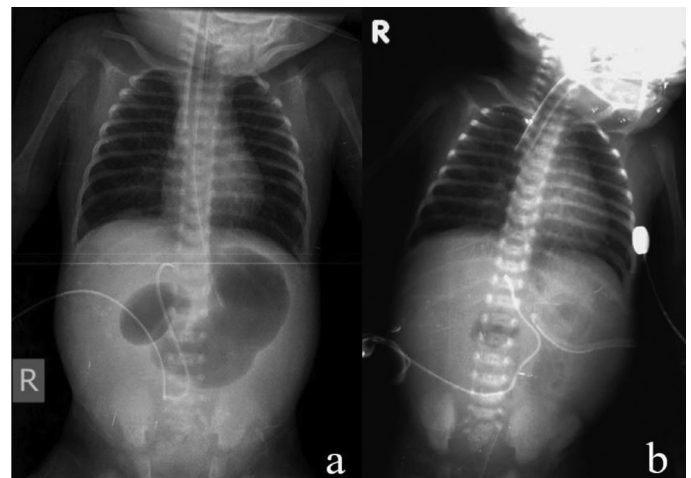
patients with TA. Normally, removing extra air from the stomach improves ventilation by reducing pressure on the diaphragm. The bradycardia attacks occurring in the case with duodenal atresia in this study may be related to pressure changes due to gastric decompression. In addition, it can be thought that duodenal atresia provides the appropriate pressure in the preoperative period, enabling the lungs to be ventilated from the TEF without any problems. Prevention of pneumonia caused by reflux of gastric fluids or saliva may be the long-term benefit of decompression<sup>(10)</sup>.

The diagnosis of airway obstruction in the prenatal period requires some precautions to be taken. In this condition, the most commonly used and most effective method is the EXIT (ex utero intrapartum treatment) procedure. In this method, the infant born by cesarean section is evaluated for possible airway obstruction before the umbilical cord is clamped (while fetal circulation continues) and tracheal intubation is provided if possible. When intubation is not possible, airway safety is ensured by emergency tracheotomy<sup>(11)</sup>. In this study, the EXIT procedure was not performed in the case who had no prenatal diagnosis, and lung ventilation was provided with an intubation tube placed in the esophagus of the patient who did not have the possibility of intubation or tracheotomy due to TA.

This recent case is very unique among the literature on TACRD and VACTERL associations for four reasons, although the patient was lost as a result of sudden cardiac arrest on the 3<sup>rd</sup> postoperative day. First of all, TA was confirmed by initial postnatal examination and subsequent imaging. Secondly, our patient was a



**Figure 2.** Floyd's TA classification (a) and type II TA (b) with TEF (Asterisk: Endotracheal tube inserted esophagus. (a) is from <https://entokey.com/congenital-tracheal-anomalies/#fig1>)



**Figure 3.** Preoperative (a) and postoperative (b) chest X-rays

case with multiple organ anomalies consistent with all TACRD and VACTERL associations. Third, despite having TA, the patient's lungs were expanded and oxygen saturation remained above 90% after esophageal intubation due to duodenal atresia. Fourth, abdominal esophageal band ligation performed before duodenal atresia repair ensured the infant's survival for three more postoperative days.

In conclusion, TA is a very rare congenital anomaly that causes postnatal respiratory distress and makes intubation impossible or complicated. This case is unique in that it includes all components of the TACRD and VACTERL associations. Detection of tracheal occlusion in the prenatal period may prevent the possible bad consequences of hypo-oxygenation in the infant. Esophageal band ligation is a viable method that provides lung ventilation from TEF by keeping the pressure in the gastrointestinal tract at an appropriate level.

### Ethics

**Informed Consent:** During the hospital stay, informed consent was obtained from the patient's family that scientific studies could be conducted in the future.

**Peer-review:** Externally peer reviewed.

### Author Contributions

Surgical and Medical Practices: S.C., A.C., Concept: S.C., C.G., A.C., Design: S.C., C.G., A.C., Data Collection or Processing: S.C., S.S.M., Analysis or Interpretation: C.G., A.C., Literature Search: S.C., S.S.M., Writing: S.C., S.S.M.

**Conflict of Interest:** The authors have no conflict of interest to declare.

**Financial Disclosure:** The authors declared that this study has received no financial support.

### REFERENCES

1. Krishnamurthy K, Kochiyil J, Poppiti RJ. Tracheal agenesis with esophageal atresia: an autopsy case report of a variant incompatible with life. *Fetal Pediatr Pathol.* 2020;39(1):45-50. doi: 10.1080/15513815.2019.1627628.
2. Gaerty K, Thomas JT, Petersen S, Tan E, Kumar S, Gardener G, Armes J. Tracheal Atresia with Segmental Esophageal Duplication: An Unusual Anatomic Arrangement. *Pediatr Dev Pathol.* 2016;19(2):154-8. doi: 10.2350/15-08-1685-CR.1.
3. Smith MM, Huang A, Labbé M, Lubov J, Nguyen LHP. Clinical presentation and airway management of tracheal atresia: A systematic review. *Int J Pediatr Otorhinolaryngol.* 2017;101:57-64. doi: 10.1016/j.ijporl.2017.07.028.
4. Krause U, Rödel RM, Paul T. Isolated congenital tracheal stenosis in a preterm newborn. *Eur J Pediatr.* 2011;170(9):1217-21. doi: 10.1007/s00431-011-1490-x.
5. Yadav P, Bajaj H, Chhabra R, Sharma D. Preterm Newborn with Isolated Congenital Tracheal Stenosis: A Very Rare and Fatal Condition. *Sch J App Med Sci.* 2014;2(6C):3036-7. doi: 10.36347/sjams.2014.v02i06.038.
6. Floyd J, Campbell DC Jr, Dominy DE. Agenesis of the trachea. *Am Rev Respir Dis.* 1962;86:557-60. doi: 10.1164/arrd.1962.86.4.557.
7. Saccardi C, Ludwig K, Cosmi E, D'Antona D, Salmaso R, Fassina A. Tracheal agenesis with bifurcating common airway arising from midesophagus. *Pediatr Dev Pathol.* 2010;13(3):252-4. doi: 10.2350/09-04-0636-CR.1.
8. Xu GQ, Zhou QC, Zhang M, Pu DR, Ouyang Z. TACRD and VACTERL associations in a fetus: case report and review of the literature. *Int J Pediatr Otorhinolaryngol.* 2013;77(12):2081-5. doi: 10.1016/j.ijporl.2013.09.016.
9. Das AK, Iyer VK. The TACRD association is distinct from VACTERL association--a case report. *Indian J Pathol Microbiol.* 2004;47(1):61-4.
10. Smith MC, Kiefer A, Bailey CE. Unsuccessful Intubation and Stabilization by Laryngeal Mask Airway in the Delivery Room: A Case of Tracheal Atresia. *Case Rep Pediatr.* 2021;2021:9983153. doi: 10.1155/2021/9983153.
11. Cansaran S, Cerrah Celayir A, Moraloğlu S, Ayvaci H, Tuğrul S, Ovalı F, Çetiner H. The EXIT for Prenatally Diagnosed Cervical Cystic Teratoma: A Case Report. *J Neonatal Surg.* 2015;4(2):18.